

## Augmentation Mammoplasty at the Premuscular Plane

EL-SAYED IBRAHIM EL-SHAFFEY, M.D.

*The Department of Plastic Surgery, Faculty of Medicine, Mansoura University.*

### ABSTRACT

In order to optimize the outcomes of breast augmentation in patients presenting with mammary hypoplasia, empty breasts following lactation, numerous variables such as incision location, pocket plane, type of implant and individual tissue characteristics must be considered. Subpectoral augmentation causes flattening and distortion of the breast when the muscle is contracted and will not translate into the desired breast fullness. It is proposed that moving the implant location to the premuscular plane prevents distortion of the breast with contraction of the pectoralis major muscle and achieves better filling of empty breasts. In patients with diminished breast tissue thickness, covering the implant with pectoral fascia avoids rippling above the areola and gives the breast a natural contour. Also, adequate covering of a proper size implant in a wide pocket reduces complications. In this paper we present our experience with augmentation mammoplasty using the premuscular plane. A total of 34 patients underwent submammary premuscular breast augmentation using round silicone gel prosthesis. Twenty-two patients underwent subglandular augmentation. Twelve patients, with diminished breast tissue thickness, underwent subfascial augmentation. A minimal incision was made in the planned lowered inframammary fold to increase the relatively short nipple inframammary distance and centralize a round implant. Dissection of the subfascial pocket was performed deep to the pectoral fascia and the subglandular pocket deep to the deep layer of superficial fascia. A wide pocket was dissected to accommodate average size prosthesis and a drainage tube in the pocket facilitated placement of the implant without excessive force by removing air behind prosthesis. A small hematoma was observed after sub-fascial augmentation in one patient. There were two cases of diminished nipple sensation after subfascial and three cases after subglandular augmentation. The results were satisfactory with a natural breast shape, a smooth transition between the soft tissues and implant in the upper pole and low morbidity. There were no capsular contractures. A wide pocket with a proper size implant allows free movement of the implant within the pocket and reduces complications. The subfascial location prevents the implant's upper part from altering its shape and position over time and combines the potential benefits of the good filling of the subglandular approach with the advantage of having more tissue available to cover the implant's upper pole. Patients are particularly happy with the natural projection of the full, soft and mobile breast that responds to gravity and postural changes.

### INTRODUCTION

As demand for breast augmentation increases patients' requirements become more refined. More

women with mammary hypoplasia, empty breasts following lactation or severe dieting want full breasts. The multitude of techniques to improve the aesthetic results indicates that still there is no universal technique for all patients [1]. To have aesthetic and symmetrically balanced breasts using implants, the surgical technique must be one that results in a soft, full, natural-looking, non-ptotic, well-positioned and mobile breast that responds to gravity and postural changes.

The submuscular approach may reduce the incidence of capsular contracture, but causes flattening or change of breast shape on muscle contraction, which will not fill empty breasts. The muscle may be divided to enhance projection at the nipple level [2], but will not improve the superior pole. Use of very large prosthesis will not translate into fullness of empty lax breasts and may be associated with complications as: Pain and discomfort, exposure of breast prosthesis, firmness and capsular contracture [3,4].

It is proposed that a premuscular location of the implant prevents flattening of the breast during muscular contraction and achieves better filling of empty breasts. Also in patients with diminished breast tissue thickness, covering the implant with pectoral fascia avoids rippling above the areola and gives the breast a nicer contour. Adequate covering of a proper size implant in a wide pocket that allows free movement of the implant reduces complications.

Based on these findings we have come to appreciate the importance of dissecting a wide subglandular pocket to contain the implant in most aesthetic breast augmentations. In patients with diminished breast tissue thickness, the implant is placed in a subfascial location to give more support. We prefer a submammary approach to prevent injury to the gland and silicone gel breast prosthesis to avoid problems of saline prosthesis as rippling or palpable

folks. We will show a strategy of breast augmentation that favors the premuscular position and define the respective place of round silicone gel implants. The goal is to determine the effect of the surgical technique (location of the pocket and relation of its size to the size of the implant) on the results.

*Anatomy:* The breast is contained within layers of the superficial fascia. The superficial layer of this fascia is not distinct from the dermis. The deep layer of superficial fascia is more distinct and can be seen on the deep surface of the breast when the breast is elevated in subglandular augmentation. There is loose areolar tissue between the deep layer of superficial fascia and the fascia that covers the pectoralis major where the subglandular pocket is developed. The pectoral fascia has its origin on the clavicle and sternum, extending toward the lateral border of the muscle to form the axillary fascia. It continues to cover the adjacent rectus abdominis, serratus anterior and external oblique. Most of the upper part of the breast lies over the pectoral fascia. The subfascial pocket is developed under the pectoral fascia. The lower portion of the breast lies over the upper portions of the external oblique and rectus abdominis and their overlying fascia.

## PATIENTS AND METHODS

From 2004 to 2007, thirty four patients presenting with mammary hypoplasia, empty breasts, following two or more lactation episodes and breast skin flaccidity without ptosis with the nipple-areola complex placed above the inframammary fold underwent breast augmentation through a submammary approach. The age range was between 18 and 38 years. Patients with concomitantly performed mastopexy were excluded. On the basis of breast tissue thickness, patients with a pinch test result of less than 2cm underwent subfascial augmentation. Other patients underwent subglandular augmentation.

### *Preoperative Marking:*

Marking is made with the patient standing in normal anatomical position, that is, with shoulders back and head straight ahead. The following points and lines are marked: The suprasternal notch-maubrium point (M), the clavicular point (C) 5.5cm lateral to the M point. The vertical line from (C) to the nipple-areola complex (C-Nip), the existing inframammary fold and the vertical line from the nipple to the middle point of the inframammary crease (Nip-Infra). A short Nip-Infra distance is noticed whereas the position of the Nipple-areola complex is usually normal. The planned lowered inframammary fold is marked in a way to increase the Nip-Infra distance so that the Nipple-areola

complex overlies the center of a round prosthesis. The boundaries of the implant pocket are further delineated. The lateral sternal and anterior axillary lines are drawn and their distance measured. Normally, we use prosthesis with a horizontal diameter 1-2cm smaller than this distance.

### *Operative technique:*

Antibiotics and methylprednisolone 125mg (reduces pain, vomiting and fatigue) are given at the beginning of the operation. With the patient under general anesthesia, a minimal incision is made in the planned lowered submammary crease (1.5-2cm below existing crease).

*Subglandular pocket:* The skin and subcutaneous tissue are incised. After sharp dissection on top of the pectoralis major fascia for 3-4cm, preparation of the pocket is then completed bluntly using finger dissection, a sponge on a stick or a large urethral dilator. Care is taken to preserve the deep layer of superficial fascia on the under surface of the breast. Superiorly, according to preoperative markings, the pocket reaches the third rib or second space. Medial dissection is taken to the lateral sternal border. The lateral dissection is taken approximately to the anterior axillary line or lateral border of the pectoralis major. We try not to exceed the anterior axillary line or the lateral border of the pectoralis muscle to prevent lateralization of the implant. At the upper and lateral poles, the skin is loosely connected to the chest wall, so care has to be taken not to overdissect the pocket superiorly and laterally. Ensure adequate covering of the implant periphery with breast tissue to avoid visible or palpable edges.

*Subfascial pocket:* In patients with reduced breast tissue pinch thickness, subfascial pocket is prepared. Incision is made in the proposed inframammary fold and the skin and subcutaneous tissue are incised. When the thin pectoral fascia is visualized, it is incised and the subfascial pocket developed. With the aid of lighted retractor, the plane between the muscle and the superficial pectoral fascia is undermined carefully by blunt dissection, using a large curved urethral dilator, to avoid fascia rupture. The fascia is more defined and resistant in the upper part and thinner and more friable in the lower part. The limits for blunt dissection are the third intercostals space superiorly, the parasternal line medially, the lateral border of the pectoral muscle laterally and the original inframammary fold or 1.5cm below it inferiorly. A gentle pushing force by the dissector could stretch the fascia and extend the subfascial pocket further at the lateral border of pectoralis major without perforating the

fascia. Careful hemostasis is important. The upper two thirds of the implant will be subfascial and the lower third subglandular (Fig. 1-A).

**Placement of implant:** After preparation of the macropocket, the patient is placed in a sitting position and a soft drainage tube with multiple holes is placed into the pocket to facilitate insertion of the sizer and implant by removing air behind the prosthesis as it is placed into the pocket (Fig. 1-B). A silicon gel sizer is placed and its position, symmetry, size of the pocket and absence of restricting bands checked. Selection of the corresponding implant size must be precise. The implant is bathed in antibiotics-saline solution and then inserted. The solution facilitates insertion by lubricating the surface. After placement of the implant into the pocket, we check symmetry and comfortable positioning of the implant. No drains are used. Wound closure in three layers, fascial, dermal and subcuticular, using long-lasting absorbable sutures. Wound adhesive is applied then steri strips and opsite dressing. An elastic support bra is used for 10 days.

**Postoperative care:** Antibiotics are prescribed for one week. Aspirin is avoided for the first two weeks. Physical exercise (especially workout) is avoided for the first 3 weeks. follow-up care consists of outpatient visits 2 and 10 days after the operation, then after 1,3,6 and 12 months. During this period, patients are instructed to call when they have severe pain not responding to pain medication, significantly more swelling or pain on one side than the other and increasing firmness of one or both breasts. Patients are instructed to massage their breasts after the second week to maintain adequate pocket and minimize the likelihood of capsular contracture.

## RESULTS

Follow-up ranged from one to three years. Implants used were textured round high profile silicone gel prosthesis, which ranged in volume from 150cc to 300cc. Twenty-two patients underwent subglandular augmentation (Figs. 2,4) and twelve patients underwent subfascial augmentation (Fig. 3). The nipple inframammary distance increased an average of 2cm and this was enough to centralize the round prosthesis behind the nipple areola complex. There were no infections, wound dehiscence or seroma. One patient had a small subcutaneous hematoma below the inframammary fold after subfascial augmentation, which resolved gradually with conservative treatment. One patient complained of transient postoperative muscle contractions on one side after subglandular augmentation, which disappeared after 10 days. Numbness

and diminished nipple sensation were reported in 5 patients (3 subglandular and 2 subfascial). They returned gradually to normal within 4-6 weeks. No evidence of implant rupture or loss of integrity was detected and no reoperations were performed on any patient during the follow-up period. The surface or contour of the breast was not affected with muscle movement. There were no cases of rippling, visible or palpable edges, asymmetry, prosthesis malposition or capsular contracture. Free implant excursion could be elicited during follow-up examinations. Avoidance of heavy prosthesis prevented development of ptosis. Patients were satisfied with the natural look of their breast and absence of the implanted look. Augmented breasts were full, soft, and mobile with natural projection.

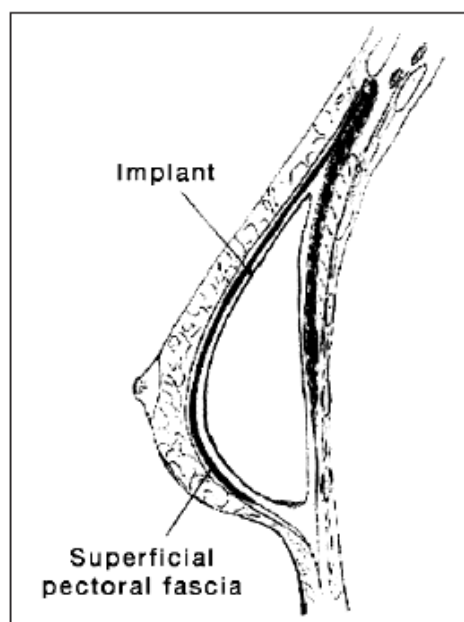


Fig. (1-A): Anatomical location of subfascial implant, below the superficial pectoral fascia and above the pectoral muscle.

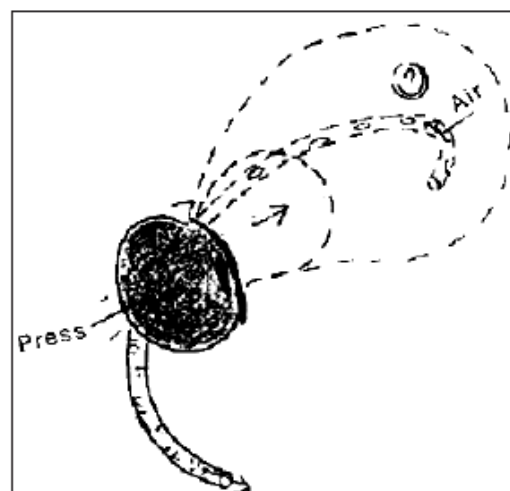


Fig. (1-B): The implant is placed easily as the drainage tube removes air behind the prosthesis.

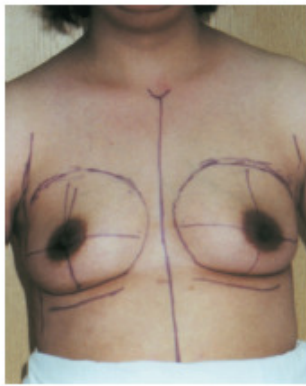

Fig. (2-A): Thirty-three-year old patient with postinvolucional hypomastia. Front view showing proposed inframammary fold.

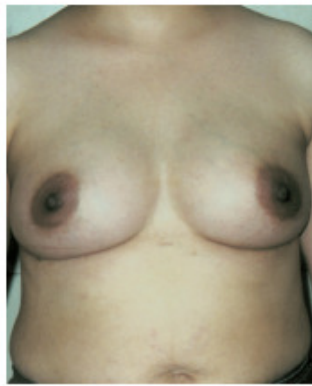

Fig. (2-B): Follow-up 1 year after subglandular augmentation with 250cc prosthesis.

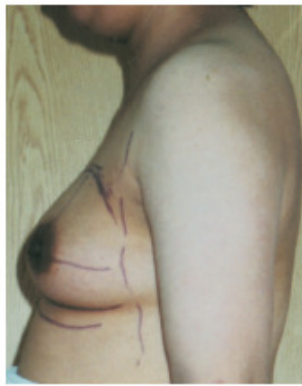

Fig. (2-C): Preoperative lateral view.

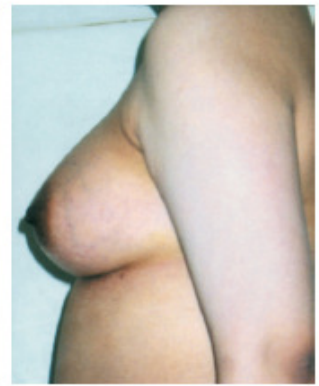

Fig. (2-D): Postoperative lateral view.

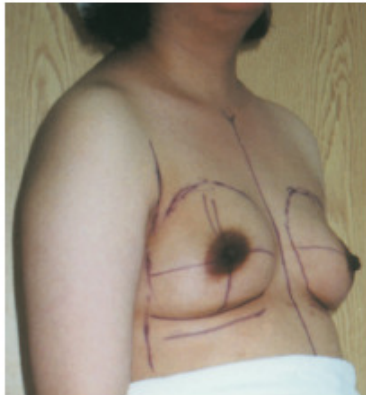


Fig. (2-E): Preoperative oblique view.

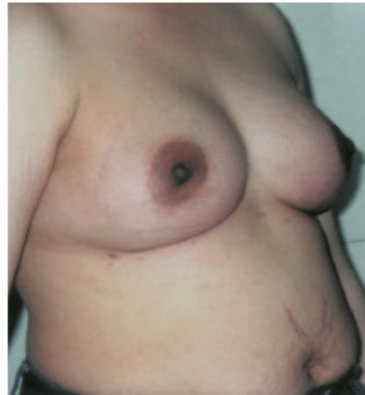

Fig. (2-F): Postoperative oblique view with full natural-looking breasts.

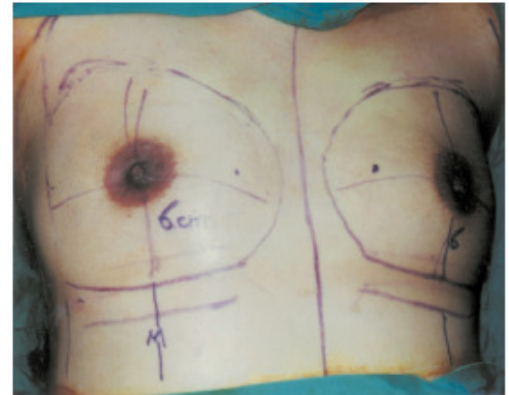


Fig. (2-G): Intraoperative view: Nipple-inframammary distance 6cm.

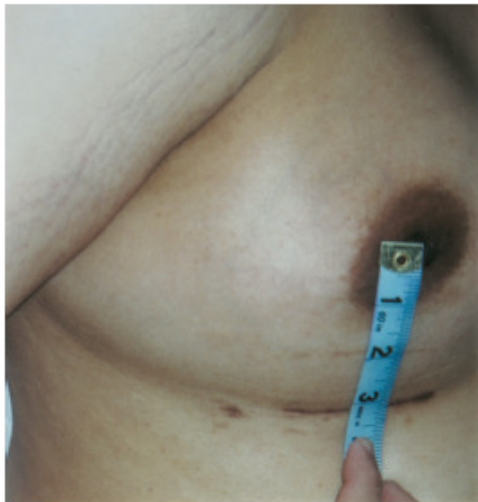

Fig. (2-H): Follow-up: Nipple-inframammary distance increased from 6 to 8cm (>3in) and remained stable, scar hidden in the new crease.

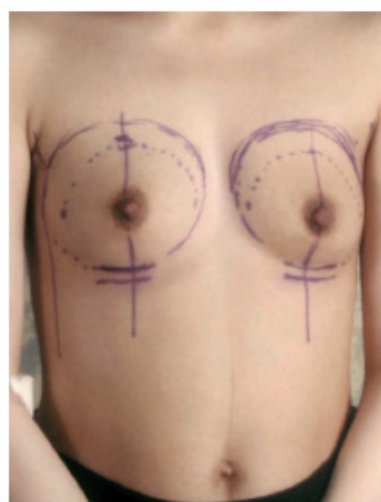

Fig. (3-A): Twenty-two-year old patient with postinvolucional hypomastia and diminished breast tissue thickness, planned inframammary fold in front view.

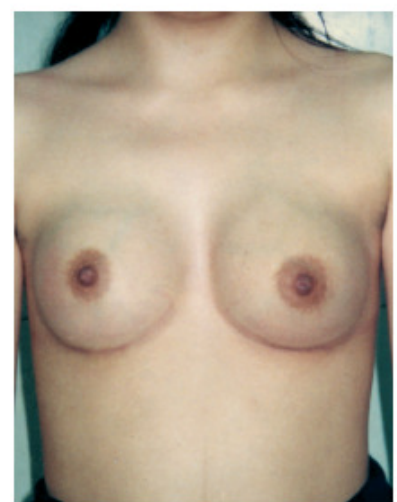

Fig. (3-B): Follow-up 2 years after subfascial augmentation with 150cc prosthesis.

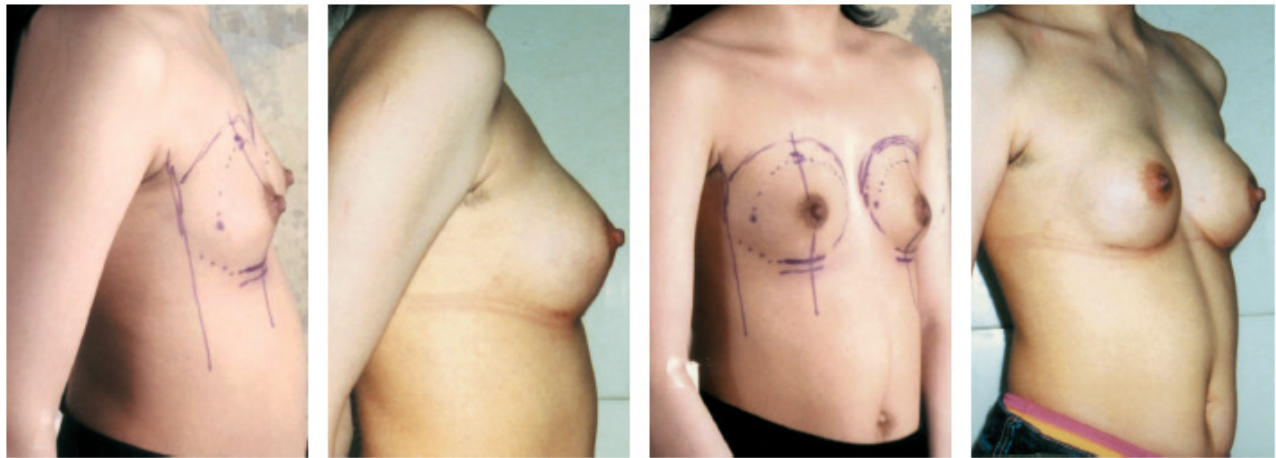


Fig. (3-C): Preoperative lateral view.

Fig. (3-D): Postoperative lateral view.

Fig. (3-E): Preoperative oblique view.

Fig. (3-F): Postoperative oblique view, with natural projection of superior pole.

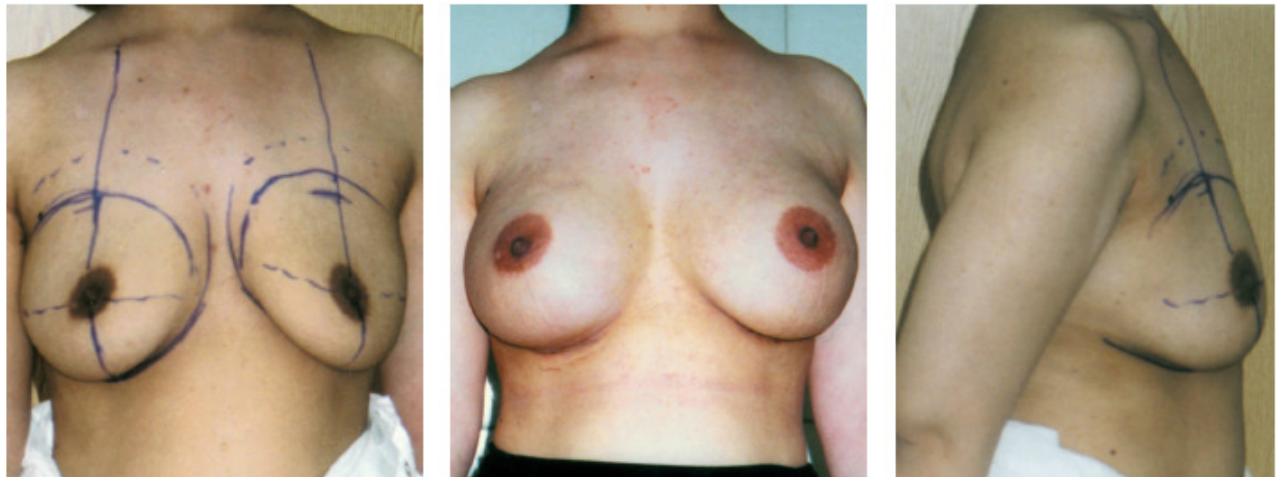

Fig. (4-A): Twenty-nine-year old patient with empty breasts following lactation. Front view with planned inframammary fold.

Fig. (4-B): Follow-up 1 year after subglandular augmentation with 225cc prosthesis.

Fig. (4-C): Preoperative lateral view.

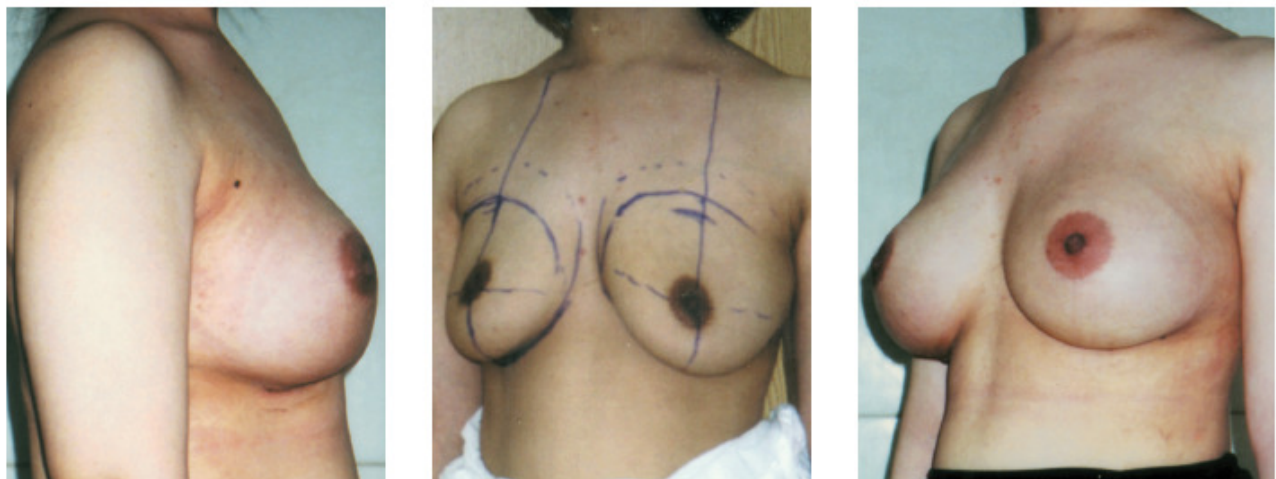


Fig. (4-D): Postoperative lateral view.

Fig. (4-E): Preoperative oblique view.

Fig. (4-F): Postoperative oblique view with mobile, full natural-looking breasts

## DISCUSSION

In augmentation mammoplasty, the selection of implant location is based on characteristics of the patients, the tissue conditions and type of the implant to ensure adequate covering of the implant [5]. The purpose of the subpectoral implant placement is to minimize rippling of saline prosthesis and lower the rate of capsular contracture. However, it is more invasive with visible flattening or distortion of the breast when the pectoral muscle is contracted. To decrease the flattening effect of muscle contraction on breast projection, partial myotomy may be performed to enhance nipple projection [6]. With the come back of silicone gel prosthesis, there is a trend to move the implant location to the premuscular plane to achieve better filling of empty breasts.

The submammary approach provides easy access to the retromammary or subfascial space without violating the gland. It leaves the gland intact, which is important for breast-feeding and preserves the fascia in subfascial augmentation. The incision is made 1.5-2cm below the existing inframammary fold to increase the relatively short nipple inframammary distance and hide the scar in the new inframammary fold. This allows the nipple-areola complex to overlie the center of the round prosthesis. A linear correlation exists between volume and nipple inframammary distance. If we place the implant and maintain the existing nipple inframammary distance, the prosthesis will lie high on the thorax and the nipple areola complex will point downward. Other authors recommended lowering the inframammary fold even more in subpectoral augmentation [1]. In our cases, the nipple inframammary distance increased an average of 2cm and this was enough to centralize the round prosthesis behind the nipple areola complex. This distance remained stable throughout the period of follow-up with no ptosis. The periareolar approach violates the gland and may disfigure the areolar-skin junction with no discernible difference in sensory outcomes [7,8]. Moreover, removal of exposed implants after periareolar augmentation may result in a depressed scar and deformity of the breast mound particularly if the conditions are not suitable for immediate replacement.

In subglandular augmentation, the implant pocket, in the retromammary space, is anatomical. In this series, adequate covering of the implant periphery with breast tissue was ensured to avoid visible or palpable edges. Proponents of the submuscular approach state that contact of the implant with the gland in subglandular location increases

the incidence of capsular contracture [9]. In this series, preservation of the deep layer of superficial fascia in the roof of subglandular pocket prevents implant-gland contact. Moreover, the pocket acquires mesothelial lining and prevents contact of the implant with the gland.

The size of the implant and its relation to the size of the pocket are important factors in prevention of complications. A relatively large implant snug in its pocket can result in pain and discomfort; implant exposure or erosion of the ribs and costal cartilages, ptosis and capsular contracture. In one report, implant was found in thoracic cavity [10]. A wide pocket with a proper size implant allows free movement of the implant within the pocket, maintains a thin film of serous fluid around the implant and reduces capsular contracture. We always maintain a wide pocket with the implant 2cm smaller to allow free mobility of the implant within the macropocket. Also adequate covering of the implant with breast tissue prevents palpable edges and avoids an implanted look. Every effort is made to ensure that the implant lies comfortably within its pocket without any pressure on the tissues. Proper massage of the breast with full excursion of the implant helps maintain sufficient space for the implant and allows the breast to remain soft. Women who choose very large implants relative to breast skin envelopes should be warned about potential adverse sensory sequelae within the nipple-areola complex [8]. In addition, use of average size prosthesis prevents ptosis development.

According to physical rules, we can put something only in an empty space [11]. The implant pocket fills up with air during the operation. The air behind the prosthesis has a resistance when it is pressed and must be drained. The drainage tube accomplishes this and facilitates placement of the implant. The advantages are minimal incision; less operative time and prevention of implant rupture by decreasing pressure.

Cohesive gel implants with adequate coverage have the potential for providing a natural breast shape and feeling, minimizing the risk of postoperative rippling and providing a greater degree of safety should the implant lose integrity [12]. Textured cohesive gel implants might be associated with fewer incidences of skin wrinkling and capsular contracture than other implants.

At the inferior border of pectoralis major muscle, the pectoral fascia becomes thin and feeble [13]. The subfascial implants will, therefore, be placed under the glandular tissue of the breast

inferiorly below the sixth intercostal space. With subfascial implants, possible shape distortion and displacement when contracting the pectoral muscle are avoided. Pectoral muscle is not detached from its insertion, resulting in less postoperative pain [14,15]. And in patients with reduced breast tissue thickness, the possibility of rippling and palpability of the implant above the areola is reduced. Subsequent breast ptosis does not increase because the fascia, in part, bears the weight of the implant and mammary gland [15]. The submammary approach, with the incision at the proposed submammary fold, maintains the integrity of the fascia. Our results are in accordance with the results of other studies [16,17] and show that the subfascial implants maintain superior pole projection and give the breast shape and contour a more natural look in comparison with the submuscular implants. Careful dissection of subfascial pocket and meticulous hemostasis are important.

Premuscular implants prevent flattening or distortion of the breast when the pectoral muscle is contracted. They also allow natural fullness of postinvoluntional empty breasts better than submuscular implants. In patients with reduced breast tissue thickness, subfascial augmentation provides proper covering and support of the implant maintaining the superior pole with a very natural projection. It combines the benefits of the good filling of the upper pole of subglandular approach without the disadvantages of the subpectoral approach. With the come back of silicone gel prosthesis, subglandular augmentation with adequate coverage of implant periphery seems to be anatomical with natural fullness. The drainage tube facilitates placement of the implant without excessive force. A wide pocket with a proper size implant allows free mobility of the implant and reduces complications. Premuscular implants have the potential of low morbidity with natural projection and soft mobile breasts that respond to gravity and postural changes in a natural way.

## REFERENCES

- Mateo J.M. and Perez M.M.V.: Innovative new concepts in augmentative breast surgery, part II: Systematic and drawing. *Aesthetic Plast. Surg.*, 25: 436, 2001.
- Panettiere P., Marchetti L., Accorsi D. and Del Gaudio G.A.: Augmentation mammoplasty of a teardrop-shaped breasts using round prosthesis. *Aesthetic Plast. Surg.*, 27: 20, 2003.
- Henriksen T.F., Holmich L.R., Fryzek J.P., Friis S., McLaughlin J.K., Hover A.P., Kioller K. and Olsen J.H.: Incidence and severity of short-term complications after breast augmentation: Results from a nationwide breast implant registry. *Ann. Plast. Surg.*, 51: 531, 2003.
- Wong C.H., Samuel M., Tan B.K. and Song C.: Capsular contracture in subglandular breast augmentation with textured versus smooth breast implants: A systemic review. *Plast. Reconstr. Surg.*, 118: 1224, 2006.
- Barbato C., Pena M., Triana C. and Zambrano A.: Augmentation mammoplasty using the retrofascia approach. *Aesthetic Plast. Surg.*, 28: 148, 2004.
- Mateu L.P. and Hernandez I.J.C.: Partial myotomy of the pectoralis major in submuscular breast implants. *Aesthetic Plast. Surg.*, 22: 228, 1998.
- Lee E.J., Jung S.G., Cho B.C. and Kim Y.B.: Submuscular augmentation mammoplasty using a perinipple incision. *Ann. Plast. Surg.*, 52: 297, 2004.
- Mofid M.M., Klatsky S.A., Singh N.K. and Nahabedian M.Y.: Nipple-areola complex sensitivity after primary breast augmentation: A comparison of periareolar and inframammary incision approaches. *Plast. Reconstr. Surg.*, 117: 1694, 2006.
- Wiener T.C.: The role of betadine irrigation in breast augmentation. *Plast. Reconstr. Surg.*, 119: 12, 2007.
- Chen Z.Y., Wang Z.G., Kuang R.X., Wang B.T. and Su Y.P.: Implant found in thoracic cavity after breast augmentation. *Plast. Reconstr. Surg.*, 116: 1826, 2005.
- Savaci N., Tosun Z. and Hosnuter M.: A simple method for breast implant placement using a drainage tube. *Aesthetic Plast. Surg.*, 28: 231, 2004.
- Brown M.H., Shenker R. and Silver S.A.: Cohesive silicone gel breast implants in aesthetic and reconstructive breast surgery. *Plast. Reconstr. Surg.*, 116: 768, 2005.
- Hwang K. and Kim D.J.: Anatomy of pectoral fascia in relation to subfascial mammary augmentation. *Ann. Plast. Surg.*, 55: 576, 2005.
- Goes J.C. and Landecker A.: Optimizing outcomes in breast augmentation: Seven years of experience with the subfascial plane. *Aesthetic Plast. Surg.*, 27: 178, 2003.
- Serra-Renom J., Garrido M.F. and Yoon T.: Augmentation mammoplasty with anatomic soft, cohesive silicone implant using the transaxillary approach at a subfascial level with endoscopic assistance. *Plast. Reconstr. Surg.*, 116: 640, 2005.
- Graf R.M., Bernardes A., Rippel R., Araujo L.R.R., Damasio R.C.C. and Auersvald A.: Subfascial breast implant: A new procedure. *Plast. Reconstr. Surg.*, 111: 904, 2003.
- Esposito G., Gravante G., Marianetti M. and DeLogu D.: Reverse dual-plane mammoplasty. *Aesthetic Plast. Surg.*, 30: 521, 2006.